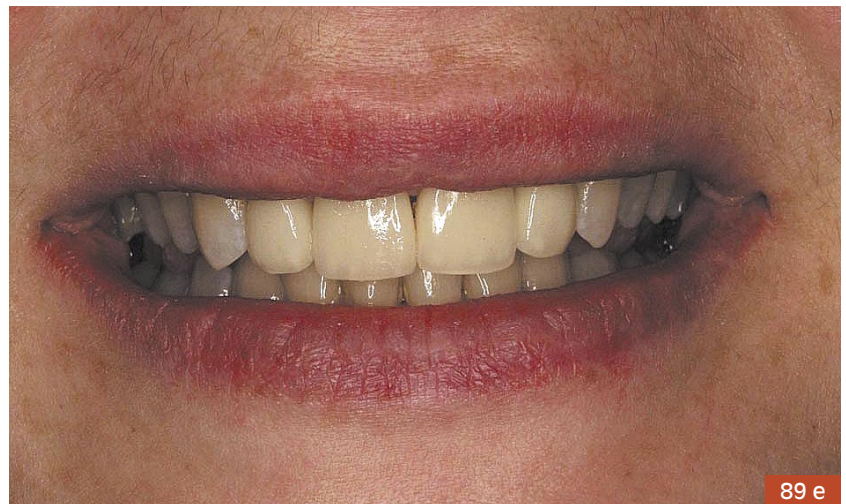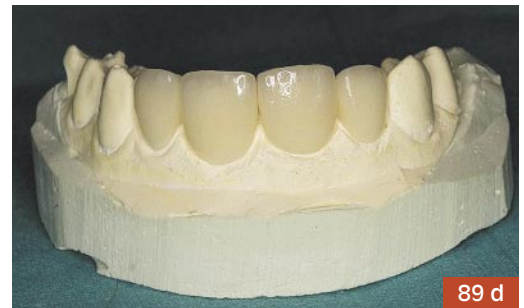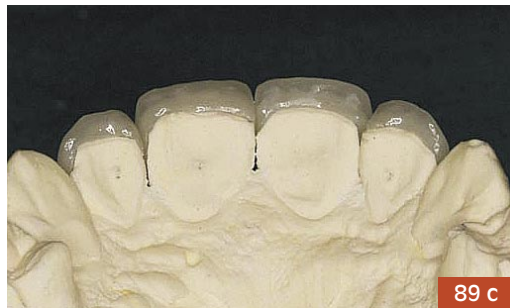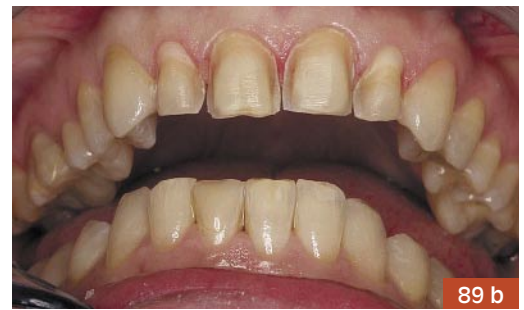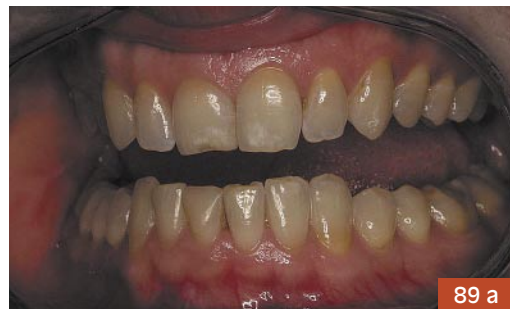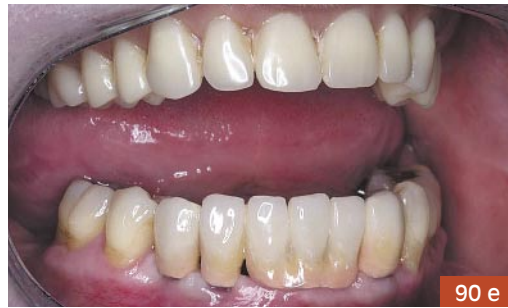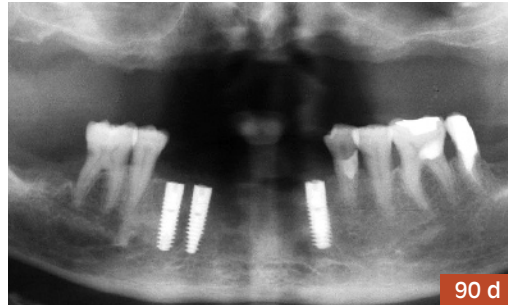


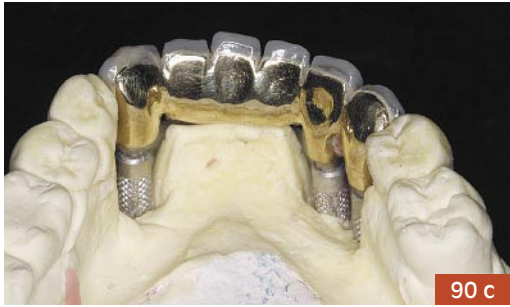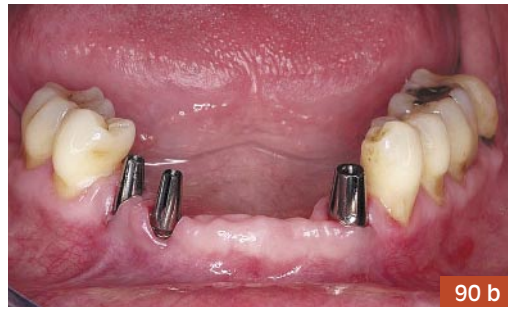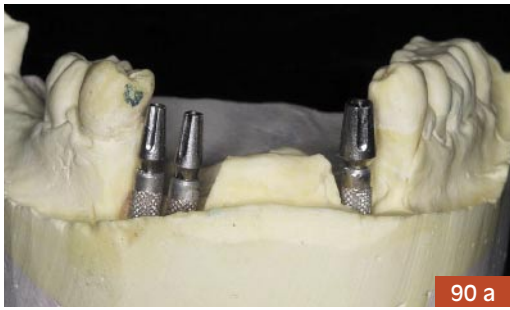**Figure 89**

- a) Discoloured dentition with opalescent, irregular patches, esthetically unacceptable. Labial aspects of 12, 11, 21, 22.
- b) Tooth preparation for porcelain veneers.

- c) The incisal edges are wrapped around on the palatal surface.
- d) Esthetic veneers on 12,11, 21, 22.
- e) Final result of the treatment.



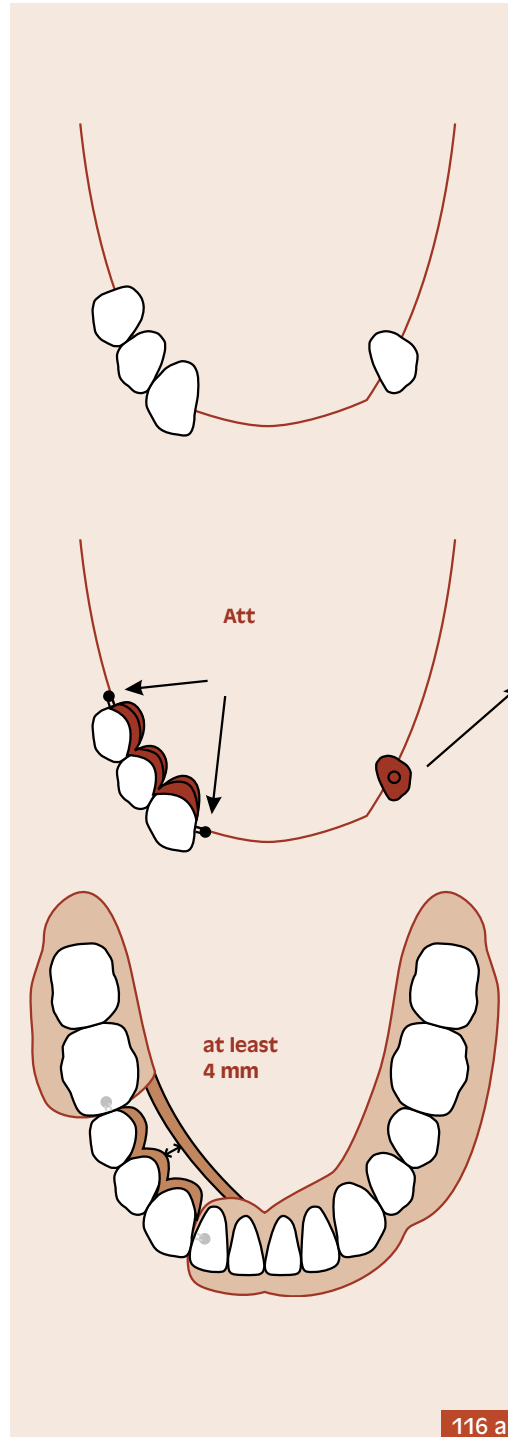
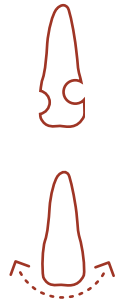
**Figure 90**

- a) Solution for extended edentulous area anterior to natural tooth of mandible – master cast with implant abutments 44, 43, and 33.
- b) Implants in situ.
- c) Gold acrylic fixed bridge – lingual aspect.
- d) Final view of fixed restoration after cementation.

Group of asymmetrically standing lower remaining teeth and lonely standing premolar. Anterior and posterior edentulous areas

## Combination of crown splint with partial overdenture

CLASS II. B.



M. Tvrdoň

Figure 116 a

### Conditions

1. Remaining teeth are filled and mobile.
2. Edentulous alveolar ridge is solid.

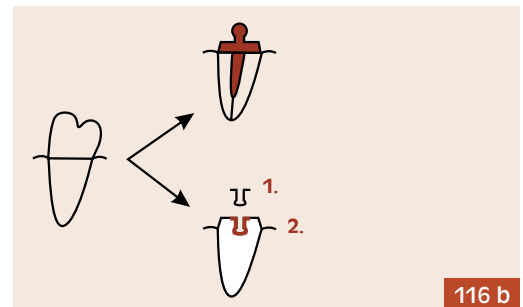


Figure 116 b

### Zest-anchore

1. Male portion - nylon
2. Female portion - metal

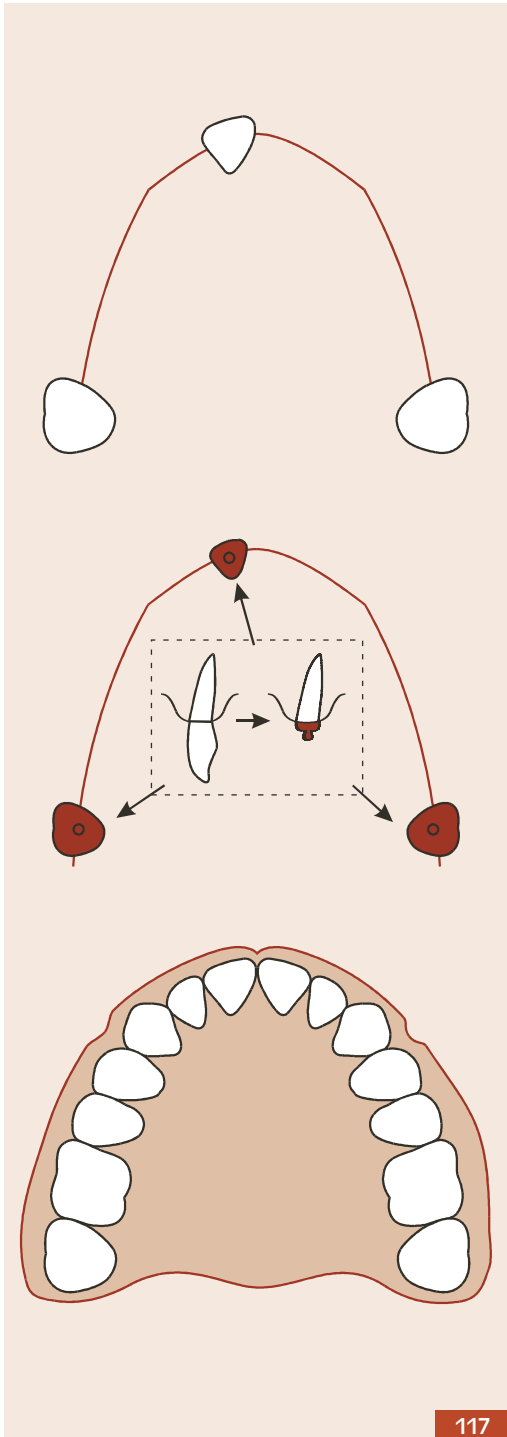
## Maxillary complete overdenture

**M. Tvrdoň**

Figure 117

### Conditions

1. Abutment teeth are carious and mobile.
2. Edentulous alveolar ridge is solid.



117

CLASS II. B.

